

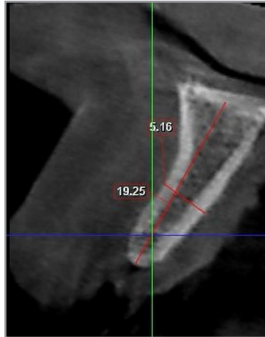
SALVIN[®]
AlloSculpt-3D[®]

***Demineralized Cortical Allograft Putty
With Cortical & Cancellous Chips***

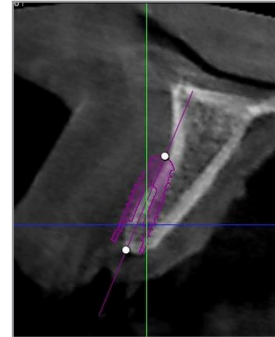
**Dr. Nick Shumaker -
Case GBR #7**



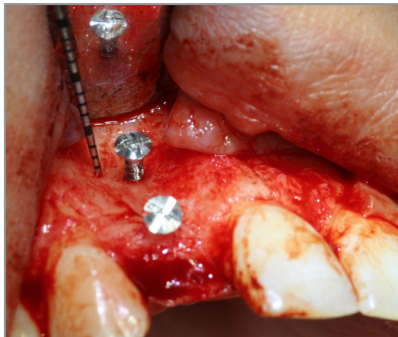
Surgery & Photos:
Dr. Nick Shumaker
Periodontist, Fort Collins, CO



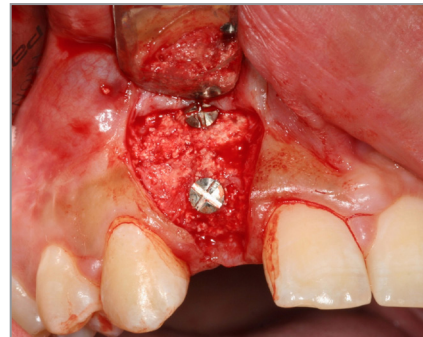
Pre-Op CBCT Scan



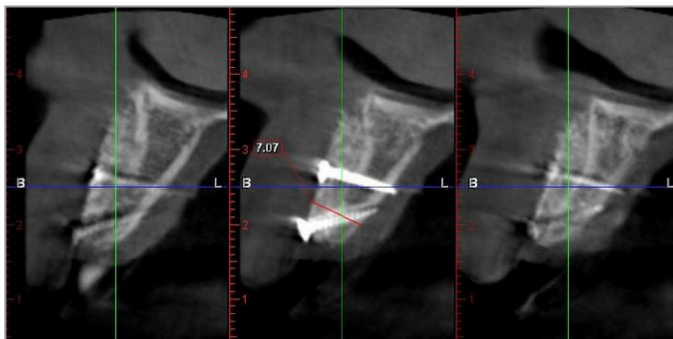
Implant Treatment Plan



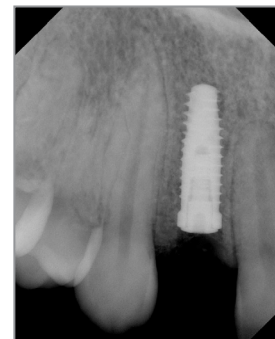
Defect With Tenting Screws



GBR After 5 Months



CBCT Scan Taken At 5 Months



Implant Placement